Serviço de Imagem Médica
Centro Hospitalar e Universitário de Coimbra
Direcção: Prof. Doutor Filipe Caseiro-Alves

Adenomas hepatocelulares – Novos conceitos e classificação molecular

Marta Barros
IFE do 4ºano de Radiologia do CHUC

27 de Setembro de 2017

Objetivos

- Epidemiologia e etiologia;
- Novo sistema de classificação dos HCA;
- Manifestações clínicas.

Objetivos

- Epidemiologia e etiologia;
  - Os adenomas são cada vez mais comuns devido à obesidade/S. metabólico, mas a incidência atual é desconhecida.
- Novo sistema de classificação dos HCA;
  - 8 classes: 3 de alto risco, 5 de baixo risco.
  - Mulheres: benefício clínico. Homens: benefício clínico duvidoso.
- Manifestações clínicas.
  - Homens: Alto risco de malignidade, independentemente do subtipo e tamanho.
  - Mulheres: baixo risco se < 5 cm

Adenoma Hepático

- Tumor benigno;
- Histologicamente são caracterizados por proliferação de hepatócitos pleomórficos
- Lesões bem circunscritas, podendo ter uma pseudocapsula fibrosa.
- Sensíveis ao ambiente hormonal: ACO, esteróides anabolizantes.
- Maioria solitários (70-80% casos) e podem ser de grandes dimensões (5-15 cm)

- Adenomatose hepática (>10 adenomas)
- Lesões múltiplas nos casos de doenças de armazenamento do glicogénio (D. von Gierke).

Fatores de risco (estabelecidos)

ACO de 1ª geração (↑estrogéneos)

Androgéneos

HCA

D. Genéticas raras

- D. armazenamento do glicogéneo
- Poliposose adenomatosa familiar
- MODY 3

D. Vasculares raras

- S. Budd-Chiari syndrome
- Agenesia da veia porta

Fatores de risco (novos)

ACO de 1ª geração (↑estrogéneos)

Nova geração de ACO
(níveis fisiológicos de estrogéneos)

?

Androgéneos

Obesidade/
S. Metabólico

HCA

D. Genéticas raras
- D. armazenamento do glicogéneo
- Poliposose adenomatosa familiar
- MODY 3

?

D. Hepática crónica
- Esteatose
- Esteatohepatite
- Fibrose
- Cirrose

?

D. Vasculares raras
- S. Budd-Chiari syndrome
- Agenesia da veia porta

Álcool

A epidemiologia dos adenomas está a mudar…

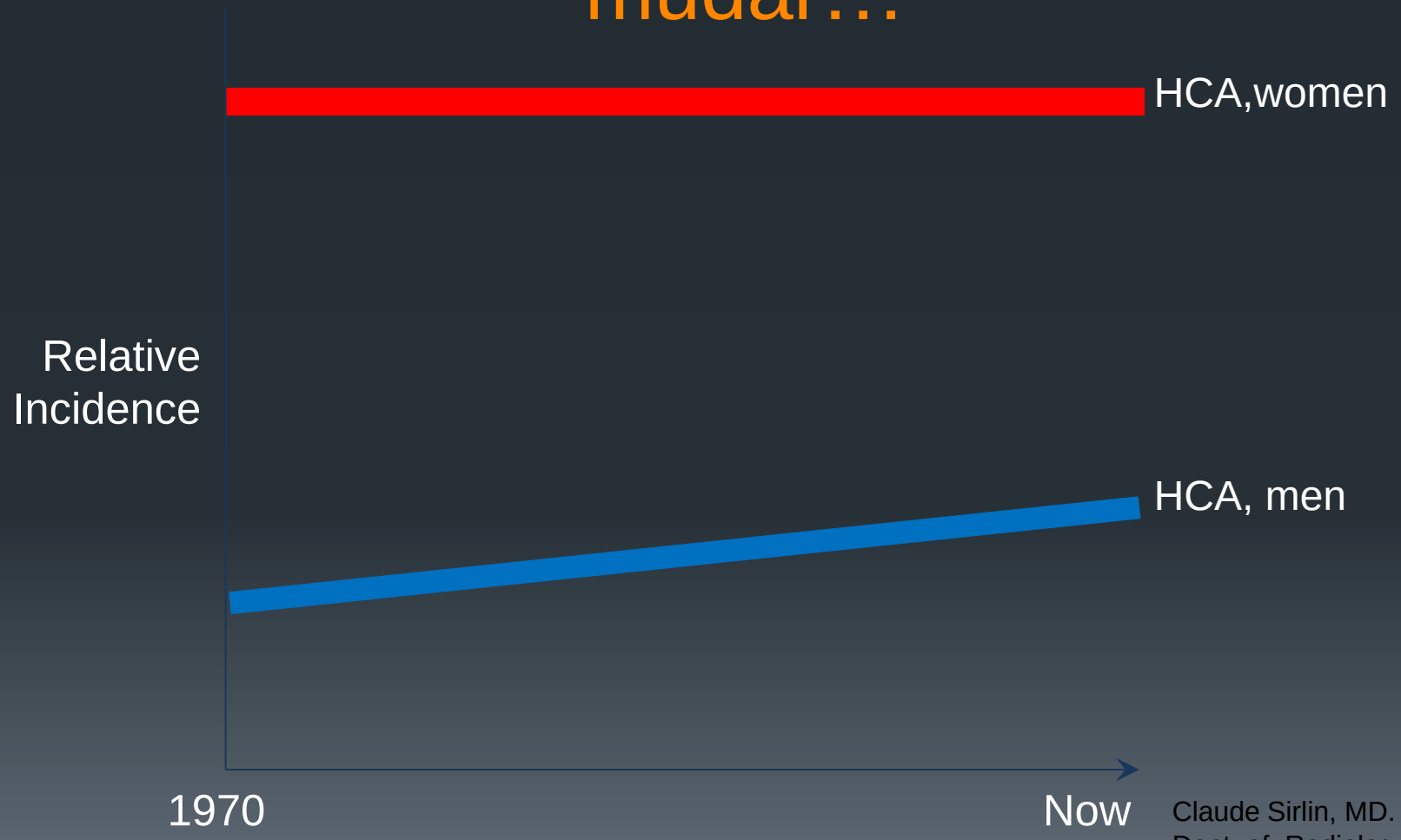

Claude Sirlin, MD.
Dept. of Radiology, US San Diego

Classificação Molecular 2006

Adenoma Inflamatório

Molecular:
- Ativação JAK/STAT

População:
- ACO
- Obesidade/S. metabólico
- Esteatose, NASH
- Glicogenose
- Álcool?

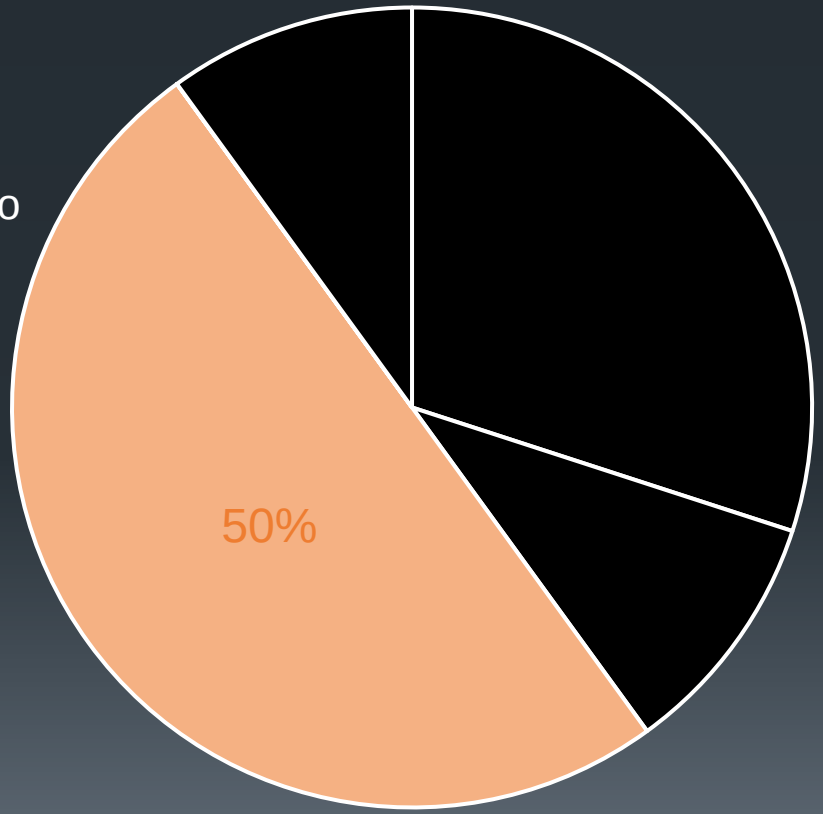

Clínica:
- Hemorragia

Histologia:
- Inflamação
- Dilação sinusoidal
- Artérias distróficas
- ± Esteatose
- ± Fibrose

Immunohistoquímica:
- PCR +
- Amilóide A +

Adenoma Inflamatório

- Lesão iso/discretamente hiperintensa em T1;
- Sem perda de sinal da fase para a oposição de fase;
- **Hipersinal em T2;**
- Realce intenso após contraste que **persiste na fase portal e tardia.**

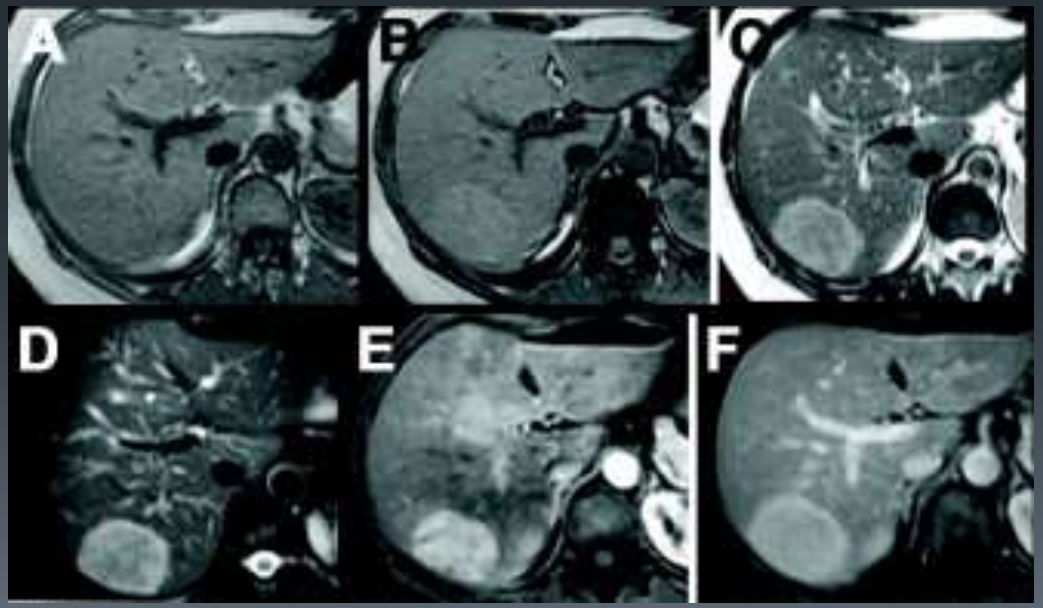

Laumonier H, Bioulac-Sage P, Laurent C, Zucman-Rossi J, Balabaud C, Trillaud H. Hepatocellular adenomas: magnetic resonance imaging features as a function of molecular pathological classification. Hepatology 2008;48(3):808–818.

Adenoma Inflamatório

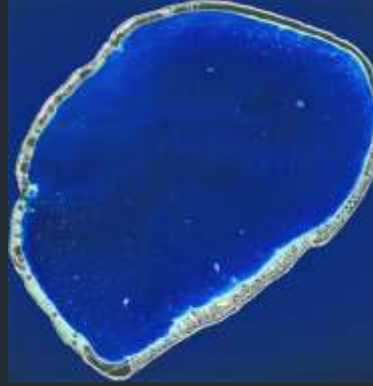

- **Sinal do Atol**
  - Presente em cerca de 50% dos casos
  - Hipersinal em T2 à periferia da lesão, com centro isointenso com o restante parênquima (dilatação sinusoidal)

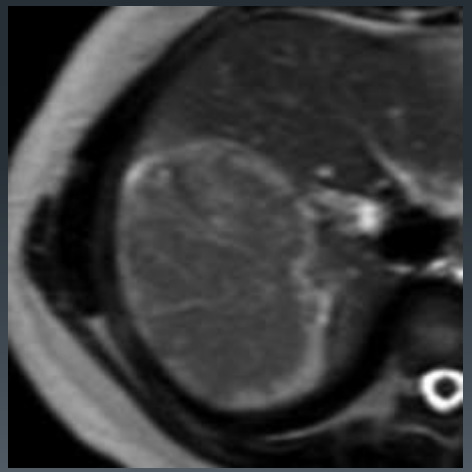

Susanna M. van Aalten, MD, Maarten G. J. Thomeer, MD, Türkan Terkivatan, MD, PhD, Roy S. Dwarkasing, MD, Joanne Verheij, MD, PhD, Robert A. de Man, MD, PhD, and Jan N. M. IJzermans, MD, PhD. Hepatocellular Adenomas: Correlation of MR Imaging Findings with Pathologic Subtype Classification. Radiology: Volume 261: Number 1—October 2011

Subtype	T1-weighted Gradient-Echo MR Images	T2-weighted MR Images	Gadolinium-enhanced T1-weighted MR Images
Inflammatory hepatocellular adenoma	Isointense or mildly hyperintense, without signal drop-off with use of chemical shift sequence	Diffusely hyperintense	Intense enhancement during arterial phase that persists in the portal venous and delayed phases
HNF-1α–mutated hepatocellular adenoma	Hyper- or isointense, with diffuse signal drop-off with use of chemical shift sequence	Isointense to slightly hyperintense	Moderate enhancement in the arterial phase, with no persistent enhancement in the portal venous and delayed phases
β-Catenin–mutated hepatocellular adenoma*	…	…	…

Venkata S. Katabathina, MD, Christine O. Menias, MD, Alampady K. P. Shanbhogue, MD, Jaishree Jagirdar, MD, Raj Mohan Paspulati, MD, and Srinivasa R. Prasad, MD. **Genetics and Imaging of Hepatocellular Adenomas: 2011 Update**. *RadioGraphics 2011; 31:1529–1543*

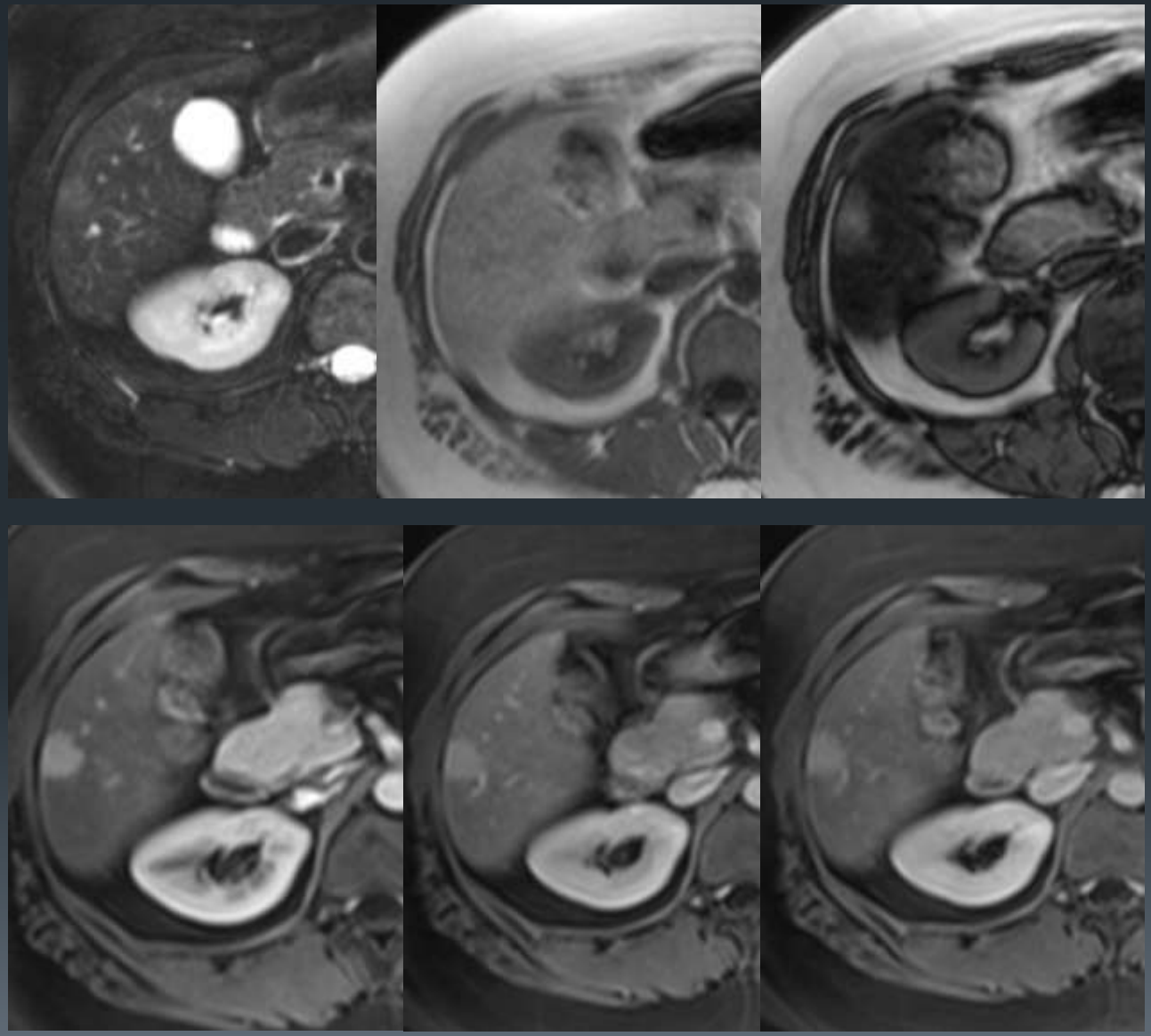

Adenoma com mutação β-catenina

Molecular:
- Ativação da via β-catenina

População:
- Esteróides anabolizantes
- Glicogenose
- Polipose adenomatosa familiar

Clínica:
- Malignização

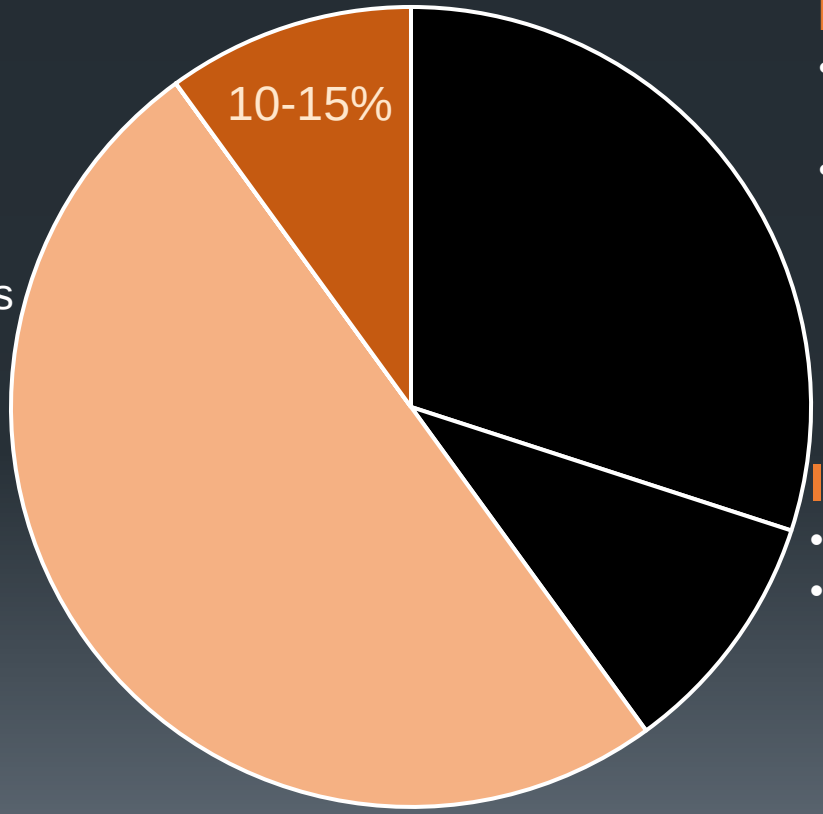

Histologia:
- Atipia arquitetural e celular
- ~HCC bem diferenciado

Immunohistoquímica:
- Sintetase da glutamina +
- ± β-catenina

Adenoma com mutação β-catenina

- Presença de cicatriz central
- Áreas de hipersinal em T2 mal delimitadas e heterogéneas
- Sem perda de sinal da fase para a oposição de fase

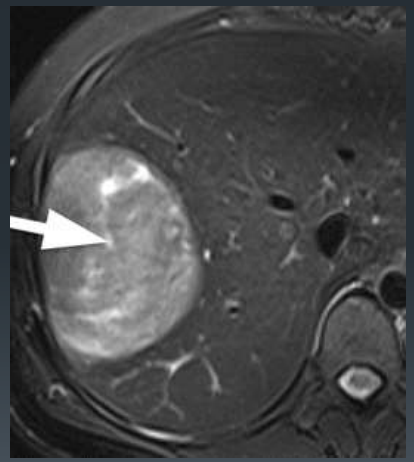

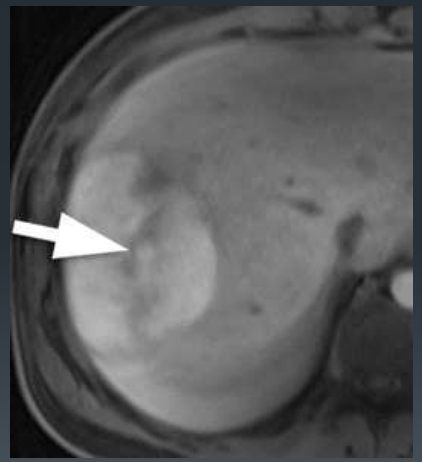

- Laumonier H, Bioulac-Sage P, Laurent C, Zucman-Rossi J, Balabaud C, Trillaud H. Hepatocellular adenomas: magnetic resonance imaging features as a function of molecular pathological classification. Hepatology 2008;48(3):808–818.
- Ahmed Ba-Ssalamah, MD Célia Antunes, MD Diana Feier, PhD, MD2 Nina Bastati, MD Jacqueline C. Hodge, MD Judith Stift, MD Maria A. Cipriano, MD Friedrich Wrba, MD Michael Trauner, MD Christian J. Herold, MD Filipe Caseiro-Alves, MD. Morphologic and Molecular Features of Hepatocellular Adenoma with Gadoxetic Acid–enhanced MR Imaging. Radiology: Volume 277: Number 1—October 2015

Adenoma com mutação β-catenina

- Discretamente hipointenso em T1
- Em T2, a lesão é isointensa com áreas hiperintensas na periferia, mal delimitadas.
- No estudo dinâmico, observa-se realce heterogéneo que mostra wash-out na fase portal e tardia.

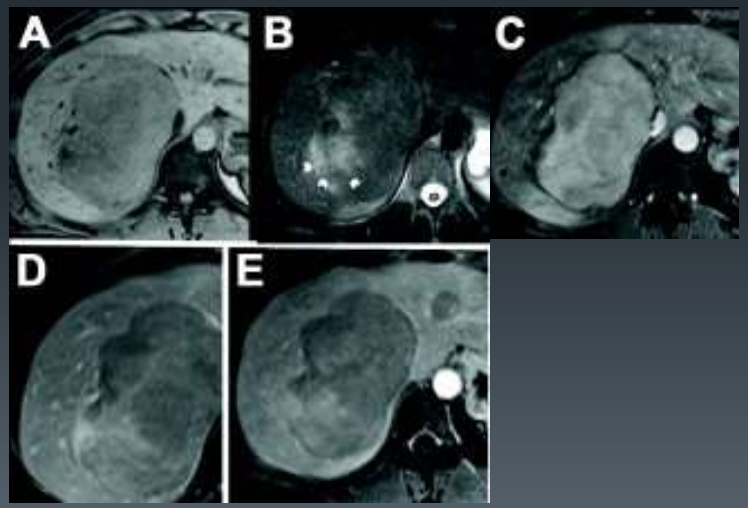

Laumonier H, Bioulac-Sage P, Laurent C, Zucman-Rossi J, Balabaud C, Trillaud H. Hepatocellular adenomas: magnetic resonance imaging features as a function of molecular pathological classification. Hepatology 2008;48(3):808–818.

Adenoma Inflamatório com mutação β-catenina

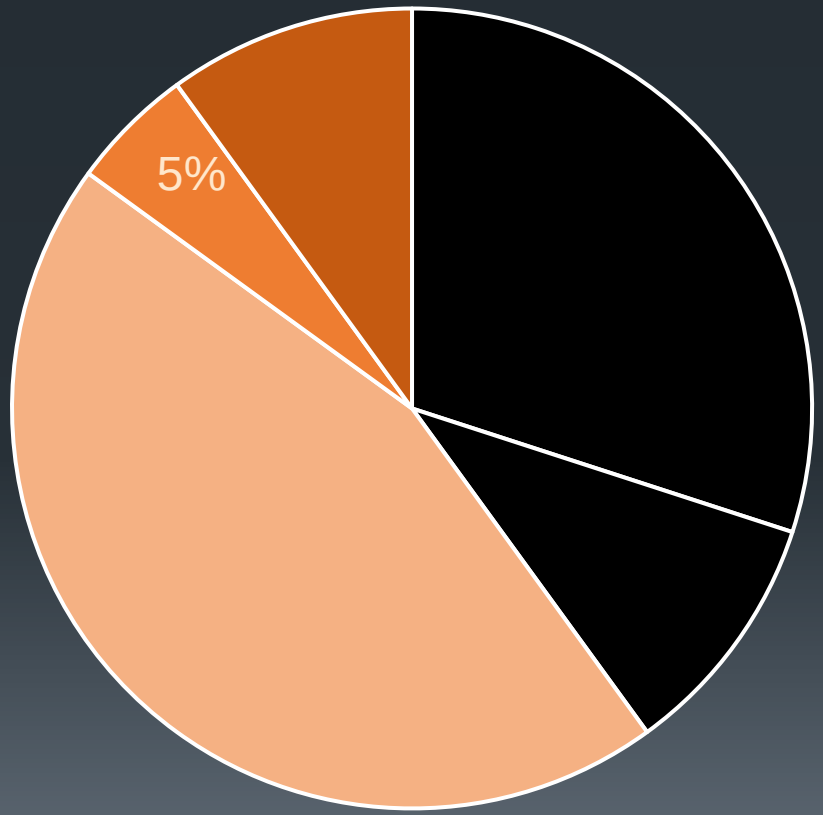

Clínica:

- Hemorragia
- Malignização

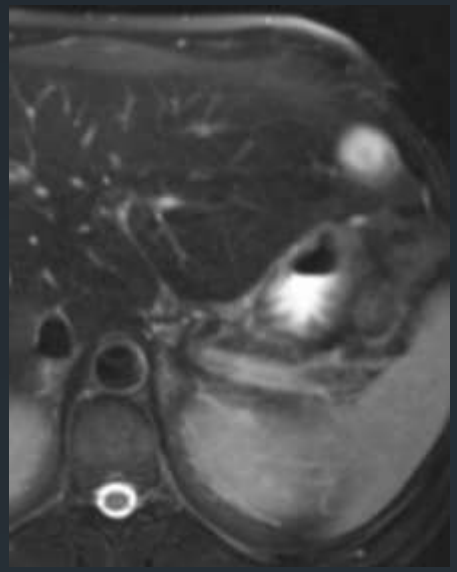

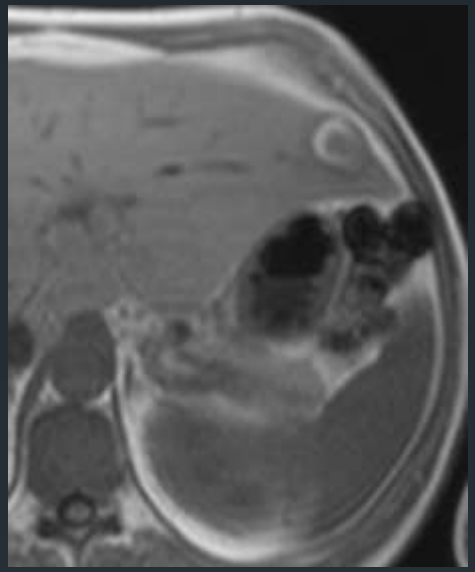

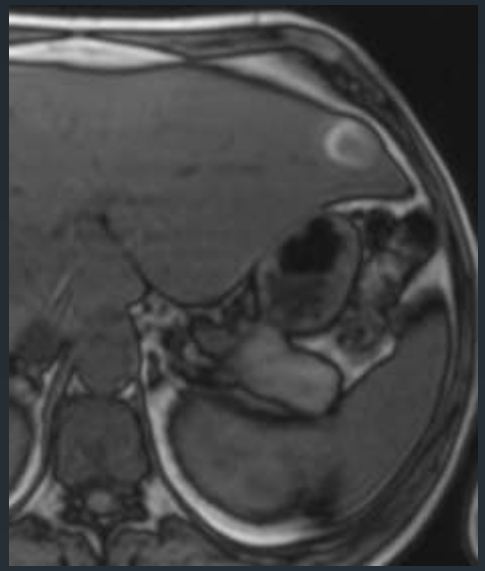

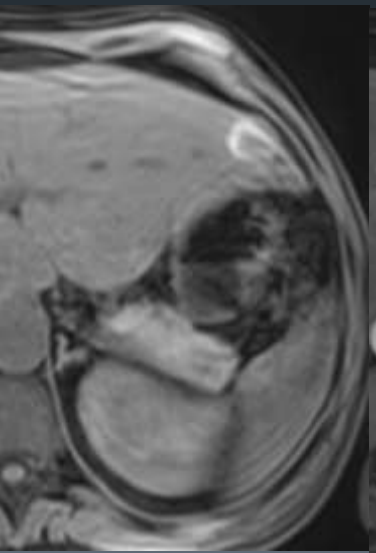

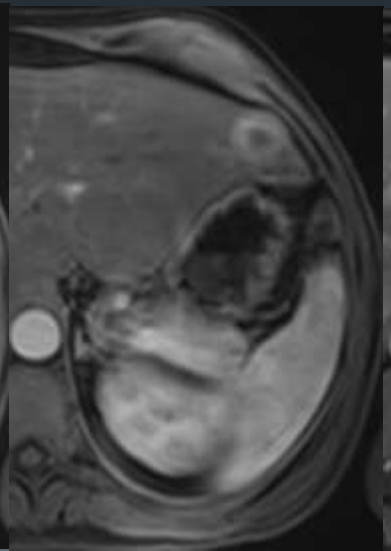

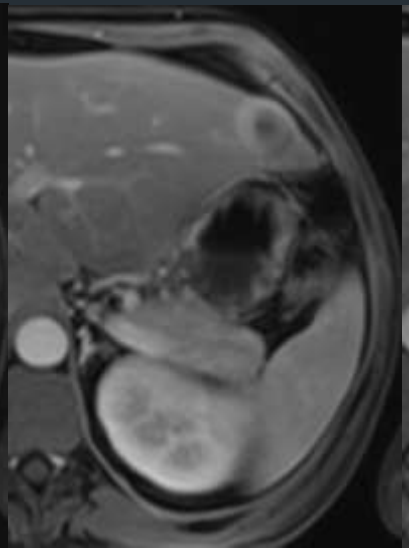

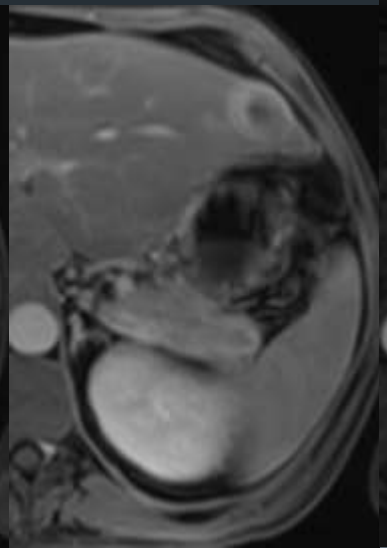

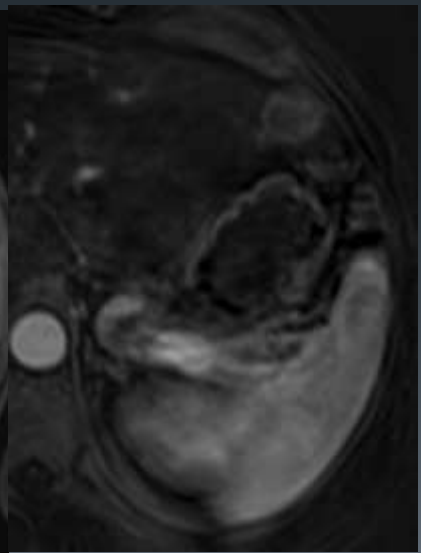

A retenção de ácido gadoxético foi observada tanto nos adenomas inflamatórios como nos adenomas com mutação b-catenina.

Apresentam aumento da expressão do transportador biliar **OATP1B1/B3**

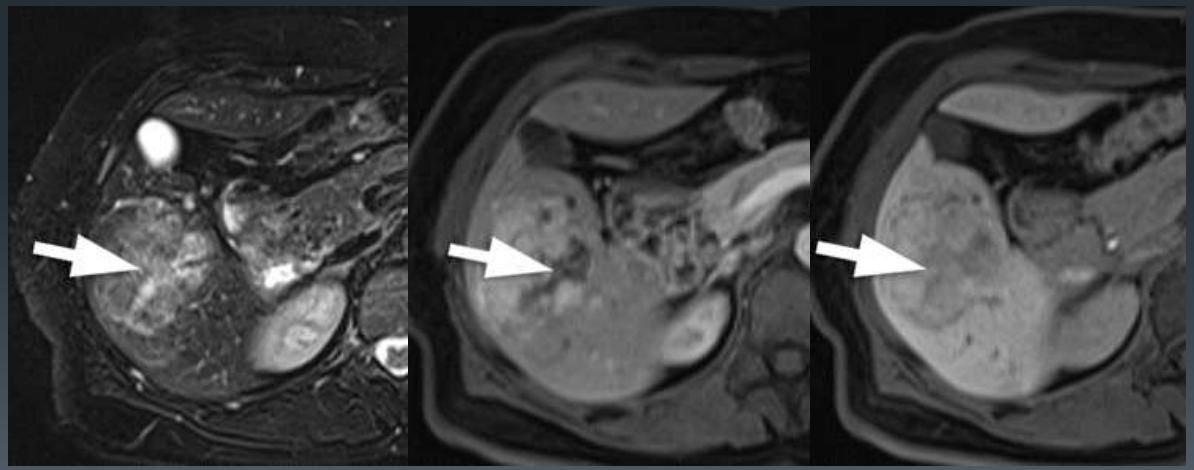

Ahmed Ba-Ssalamah, MD Célia Antunes, MD Diana Feier, PhD, MD2 Nina Bastati, MD Jacqueline C. Hodge, MD Judith Stift, MD Maria A. Cipriano, MD Friedrich Wrba, MD Michael Trauner, MD Christian J. Herold, MD Filipe Caseiro-Alves, MD. Morphologic and Molecular Features of Hepatocellular Adenoma with Gadoxetic Acid–enhanced MR Imaging. Radiology: Volume 277: Number 1—October 2015

Adenoma com inativação HNF1α

Molecular:
Inativação do gene *HNF1α*

População:
- Mulheres
- D. genéticas (não glicogenose)
- Diabetes MODY3
- “Adenomatose hepática”

Clinica:
- Indolente

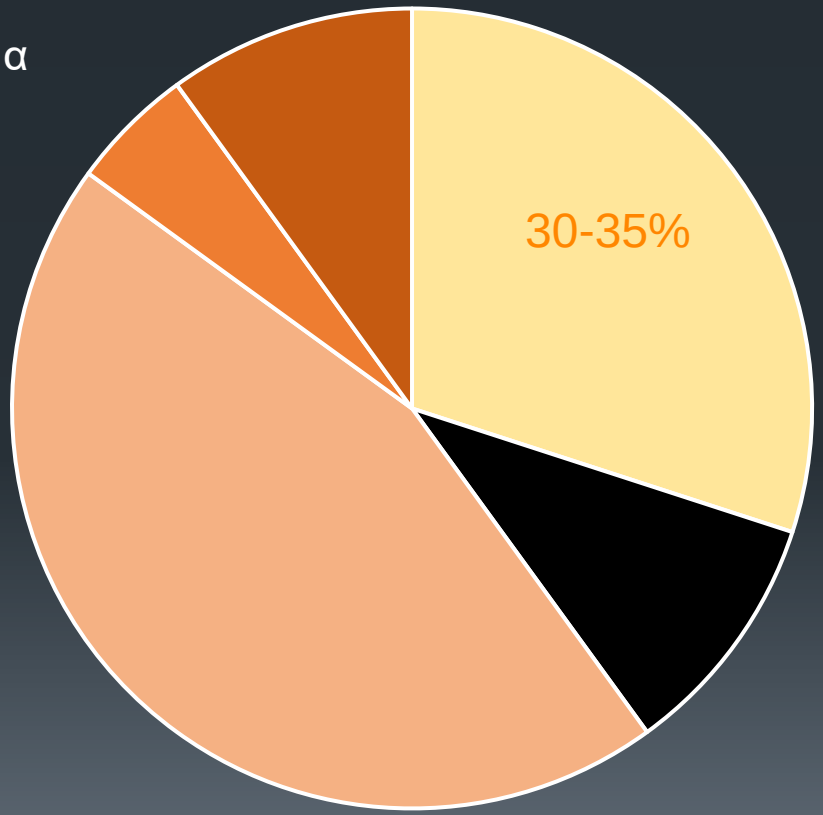

Histologia:
- Esteatose
- Sem atípia

Immunohistoquímica:
- Ausência da proteina LFABP

Subtype	T1-weighted Gradient-Echo MR Images	T2-weighted MR Images	Gadolinium-enhanced T1-weighted MR Images
Inflammatory hepatocellular adenoma	Isointense or mildly hyperintense, without signal drop-off with use of chemical shift sequence	Diffusely hyperintense	Intense enhancement during arterial phase that persists in the portal venous and delayed phases
HNF-1α–mutated hepatocellular adenoma	Hyper- or isointense, with diffuse signal drop-off with use of chemical shift sequence	Isointense to slightly hyperintense	Moderate enhancement in the arterial phase, with no persistent enhancement in the portal venous and delayed phases
β-Catenin–mutated hepatocellular adenoma*	…	…	…

Venkata S. Katabathina, MD, Christine O. Menias, MD, Alampady K. P. Shanbhogue, MD, Jaishree Jagirdar, MD, Raj Mohan Paspulati, MD, and Srinivasa R. Prasad, MD. **Genetics and Imaging of Hepatocellular Adenomas: 2011 Update**. *RadioGraphics 2011; 31:1529–1543*

Adenoma com inativação HNF1α

- Discreto hipersinal em T1 com perda de sinal da fase para a oposição de fase ➔ gordura microscópica;
- Discreto hipersinal em T2;
- Muito ligeiro realce após contraste.

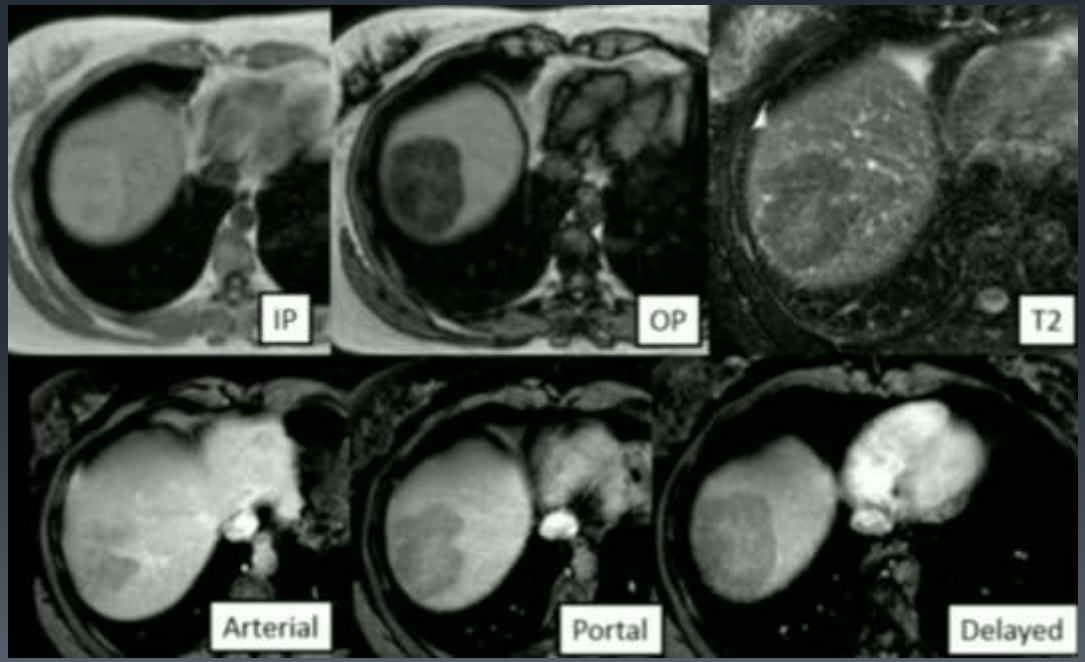

Laumonier H, Bioulac-Sage P, Laurent C, Zucman-Rossi J, Balabaud C, Trillaud H. Hepatocellular adenomas: magnetic resonance imaging features as a function of molecular pathological classification. Hepatology 2008;48(3):808–818.

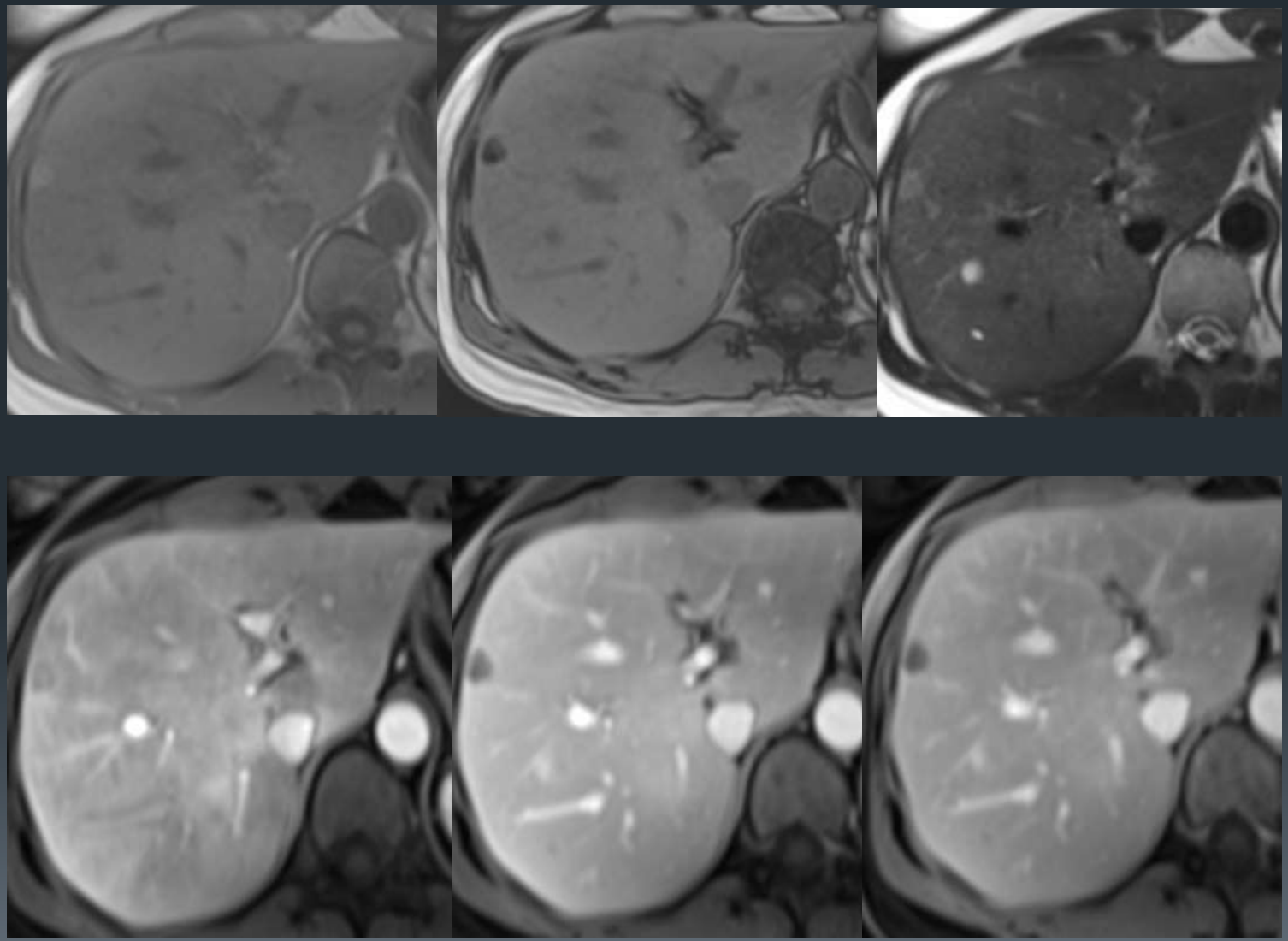

Adenomas não classificáveis

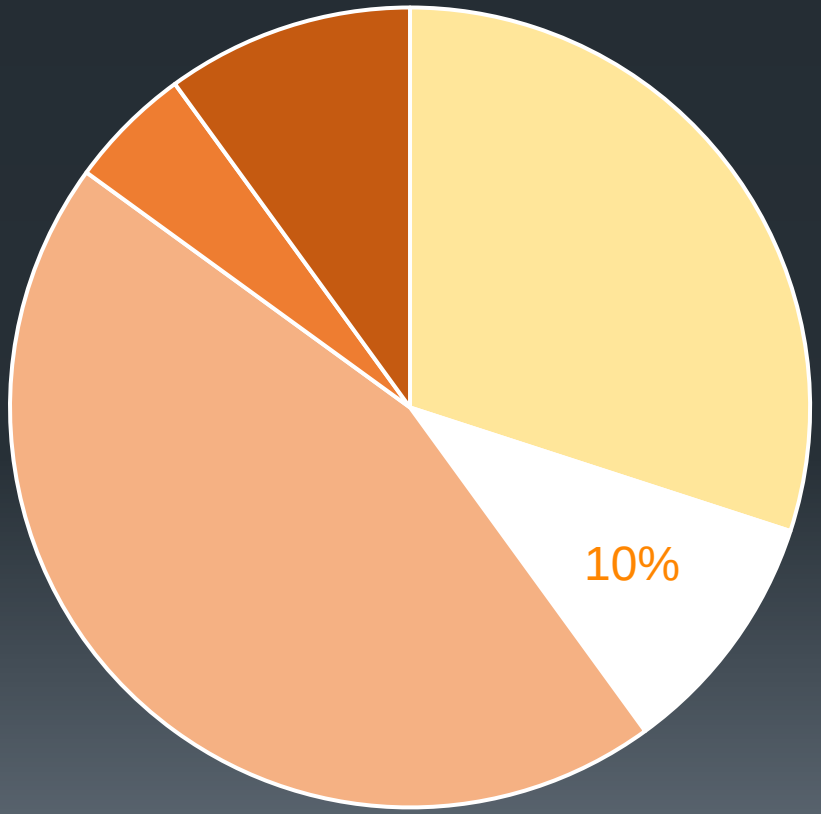

O Paradigma está a mudar…

1970 a 2000

Agora

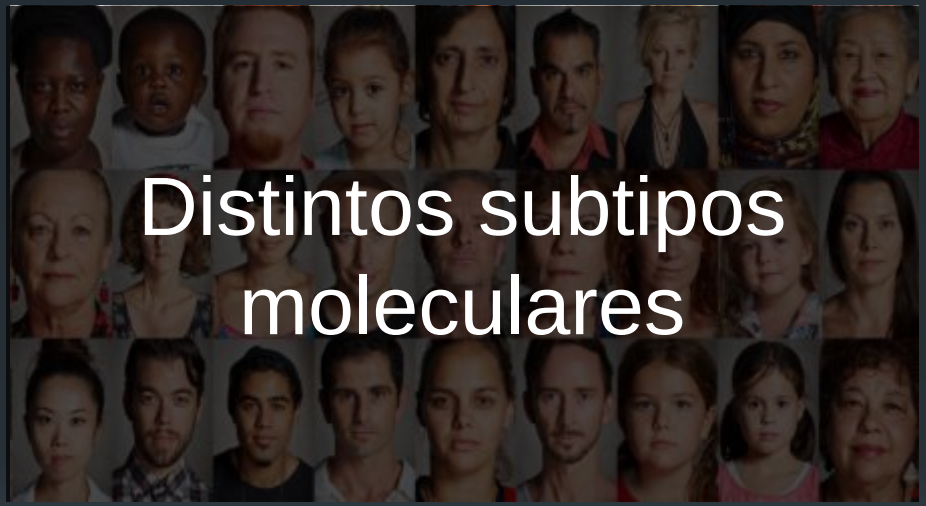

Claude Sirlin, MD. Dept. of Radiology, US San Diego

1948 — 1ª Descrição de HCA

1973 — Associação com ACO

1985 — Adenomatose

2006 — Classificação de Bordeaux

2017 — Nova classificação dos HCA

…

Classificação Molecular 2017

Gastroenterology 2017;152:880–894

BASIC AND TRANSLATIONAL—LIVER

Molecular Classification of Hepatocellular Adenoma Associates With Risk Factors, Bleeding, and Malignant Transformation

Jean-Charles Nault,[1,2,3] Gabrielle Couchy,[1] Charles Balabaud,[4] Guillaume Morcrette,[1] Stefano Caruso,[1] Jean-Frederic Blanc,[4,5] Yannick Bacq,[6] Julien Calderaro,[1,7] Valérie Paradis,[8] Jeanne Ramos,[9] Jean-Yves Scoazec,[10] Viviane Gnemmi,[11] Nathalie Sturm,[12] Catherine Guettier,[13] Monique Fabre,[14] Eric Savier,[15] Laurence Chiche,[16] Philippe Labrune,[17] Janick Selves,[18] Dominique Wendum,[19] Camilla Pilati,[1] Alexis Laurent,[20] Anne De Muret,[21] Brigitte Le Bail,[4,22] Sandra Rebouissou,[1] Sandrine Imbeaud[1]; GENTHEP Investigators, Paulette Bioulac-Sage,[4,22] Eric Letouzé,[1] and Jessica Zucman-Rossi[1,23]

2006 – Classificação de Bordeaux

2017 – Nova classificação dos HCA

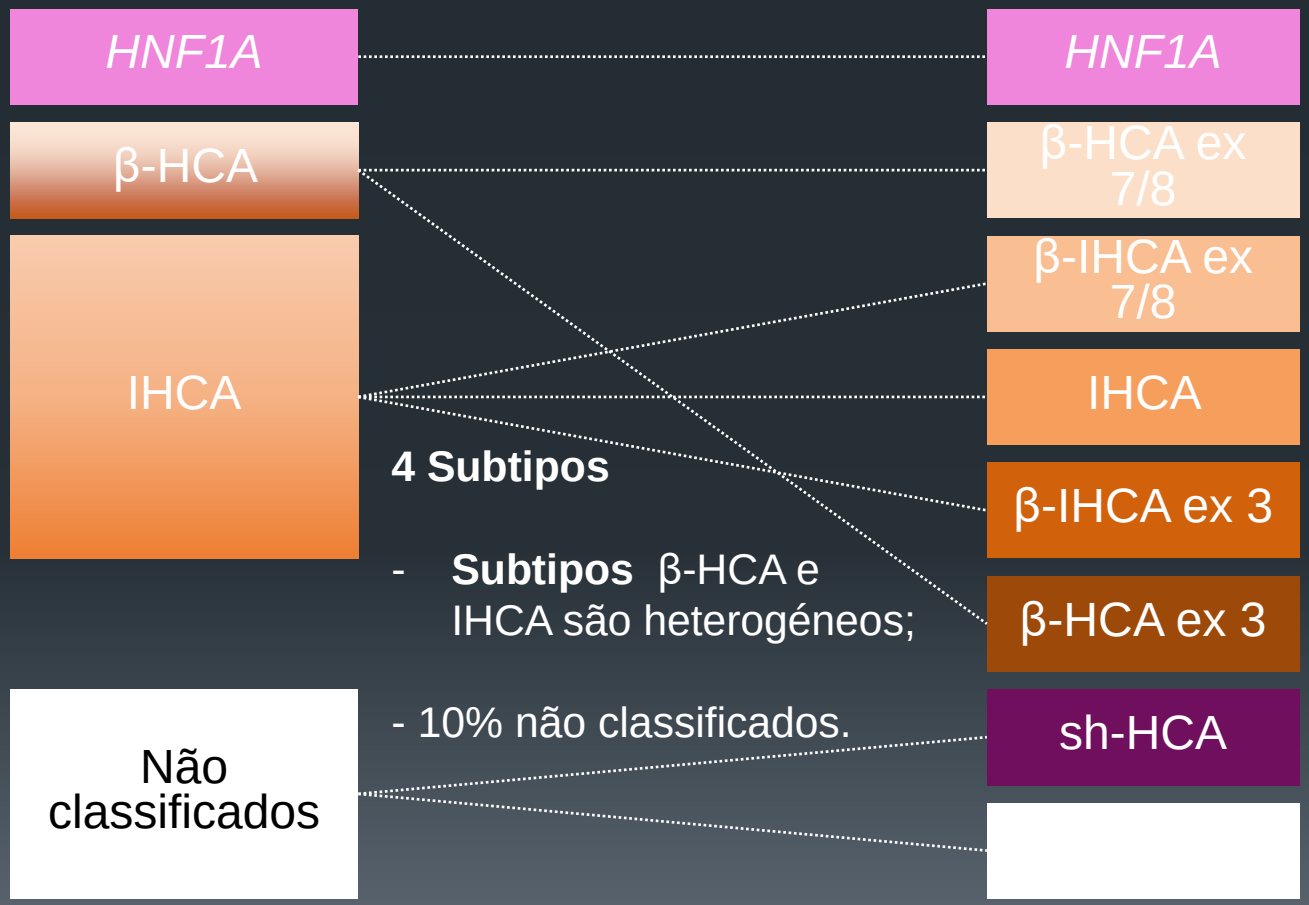

4 Subtipos

- **Subtipos** β-HCA e IHCA são heterogéneos;
- 10% não classificados.

8 Subtipos

- β-HCA eIHCA foram redefinidos;
- sh-HCA é novo;
- 7% não classificados.

Claude Sirlin, MD. Dept. of Radiology, US San Diego

Adenoma com mutação Sonic Hedgehog

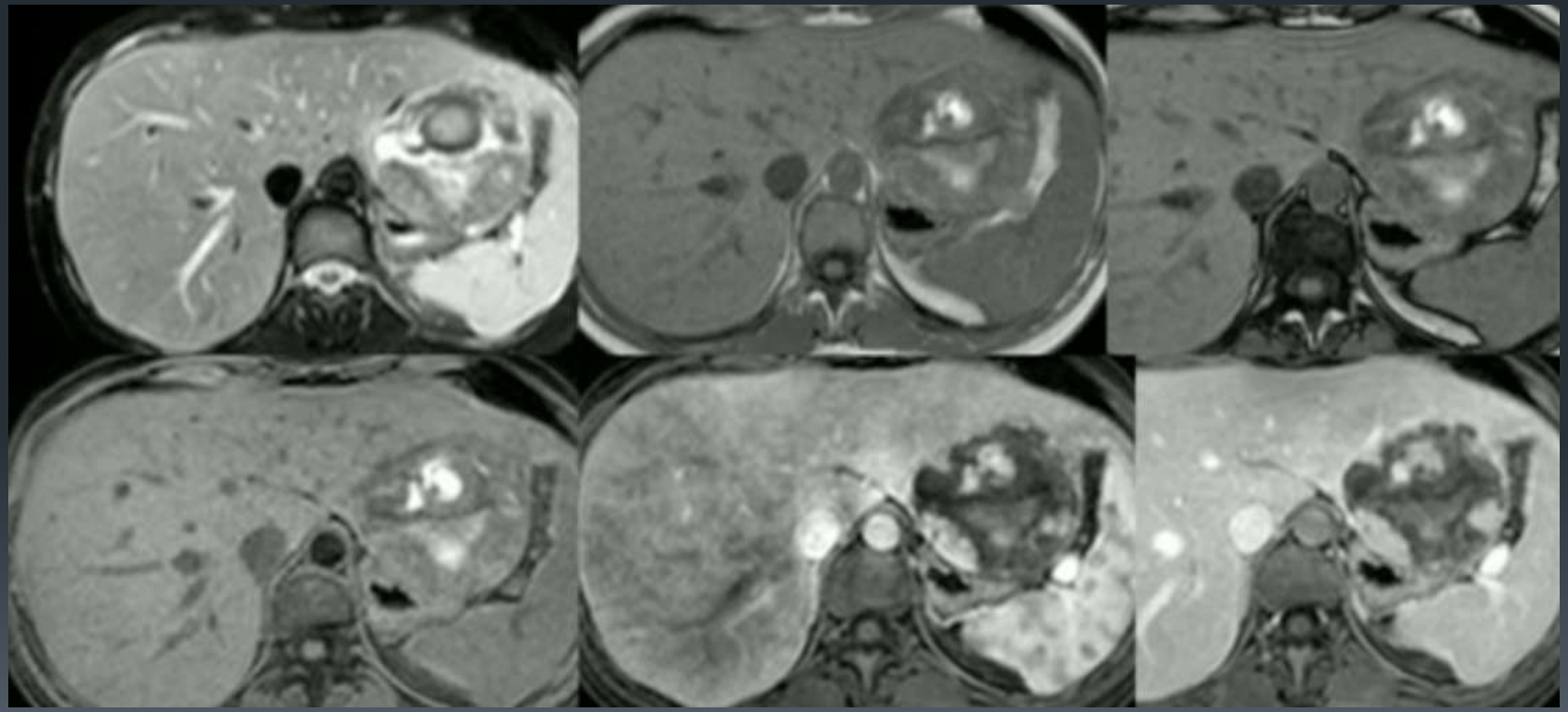

M. Ronot. Imaging hallmarks with pathological correlation. Lecture Session, ESGAR 2017.

HCA classification	H-HCA 34%	β-HCA ex 7/8 4%	IHCA 30%	β-HCA ex 3 8%	sh-HCA 4%	Unclassified 7%
Molecular pathway	HNF1A inactivation	Weak β-catenin activation	JAK/STAT pathway activation	β-catenin activation	Sonic hedgehog activation	No association
Mutation(s)	*HNF1A* biallelic	*CTNNB1* exons 7 or 8	*IL6ST, STAT3, FRK, GNAS, JAK1*	*CTNNB1* exon 3	*INBHE/GLI1* fusion	No association
Histology	Steatosis Microadenoma Less hemorrhage	Atypia No malignant transformation Hemorrhage Cholestasis	Inflammation Sinusoidal dilation Dystrophic arteries Fatty liver	Atypia ± Malignant transformation Cholestasis	Hemorrhage Fatty liver	No association
IHC	Negative liver-type fatty acid binding protein	Faint glutamine synthase	Positive C-reactive protein Positive serum amyloid A	Positive glutamine synthase	Positive prostaglandin D syntyhase	No association

Claude Sirlin, MD. Dept. of Radiology, US San Diego

HCA classification	H-HCA 34%	β-HCA ex 7/8 4%	IHCA 30%	β-HCA ex 3 8%	sh-HCA 4%	Unclassified 7%
Risk factors	Most are sporadic HNF1A germline mutations (MODY) Not glycogenosis	Unknown	Obesity Alcohol Glycogenosis OCP?	Androgens Vascular disorders	Obesity OCP?	No association
Presentation	Female "Adenomatosis"	Female Young	Male or female Older Asymptomatic Inflammatory syndrome (labs): high GGT, alk. phosphatase	Male or female Young Malignant transformation	Female Bleeding	No association

Claude Sirlin, MD. Dept. of Radiology, US San Diego

β-IHCA ex 7/8 5%

β-IHCA ex 3 8%

HCA classification	H-HCA 34%	β-HCA ex 7/8 4%	IHCA 30%	β-HCA ex 3 8%	sh-HCA 4%	Unclassified 7%
Risk factors	Most are sporadic HNF1A germline mutations (MODY) Not glycogenosis	Unknown	Obesity Alcohol Glycogenosis OCP?	Androgens Vascular disorders	Obesity OCP?	No association
Presentation	Female "Adenomatosis"	Female Young	Male or female Older Asymptomatic Inflammatory syndrome (labs): high GGT, alk. phosphatase	Male or female Young Malignant transformation	Female Bleeding	No association

Epidemiology & Etiology

Clinical Manifestations

HCA classification	H-HCA 34%	β-HCA ex 7/8 4%	IHCA 30%	β-HCA ex 3 8%	sh-HCA 4%	Unclassified 7%
Risk factors	Most are sporadic HNF1A germline mutations (MODY) Not glycogenosis	Unknown	Obesity Alcohol Glycogenosis OCP?	Androgens Vascular disorders	Obesity OCP?	No association
Presentation	Female "Adenomatosis"	Female Young	Male or female Older Asymptomatic Inflammatory syndrome (labs): high GGT, alk. phosphatase	Male or female Young Malignant transformation	Female Bleeding	No association

β-IHCA ex 7/8 5%

β-IHCA ex 3 8%

"High-Risk HCA"

Claude Sirlin, MD. Dept. of Radiology, US San Diego

HCA classification	H-HCA 34%	β-HCA ex 7/8 4%	IHCA 30%	β-IHCA ex 7/8 5%	β-IHCA ex 3 8%	β-HCA ex 3 8%	sh-HCA 4%	Unclassified 7%
Risk factors	Most are sporadic HNF1A germline mutations (MODY) Not glycogenosis	Unknown	Obesity Alcohol Glycogenosis OCP?			Androgens Vascular disorders	Obesity OCP?	No association
Presentation	Female "Adenomatosis"	Female Young	Male or female Older Asymptomatic Inflammatory syndrome (labs): high GGT, alk. phosphatase			Male or female Young Malignant transformation	Female Bleeding	No association

"Non-High-Risk HCA" "High-Risk HCA"

Claude Sirlin, MD. Dept. of Radiology, US San Diego

Manifestações clínicas

Mulheres

- Hemorragia 14-71%
- Malignidade 0-18%

Homens

- Hemorragia 5-6%
- Malignidade 41-65%

Diagnóstico diferencial dos Adenomas baseado no contexto clínico

	H-HCA	IHCA	β-IHCA	β-HCA	Não classificável
Mulheres sob ACO	++	++	+	+	+
Mulheres obesas	+	++	++	+	+
Homens obesos	—	++	++		
Androgéneos	—			++	
Álcool	—	?			
Alt.vasculares	—	?		?	
Glicogenose	—	++	+	+	
Polipose adenomatosa familiar			+		
MODY 3	++		+		

Claude Sirlin, MD. Dept. of Radiology, US San Diego

Adenomas Pigmentados (“dark adenomas”)

- Descritos apenas 11 casos na literatura[1]
- ++ Homens
- Adenomas hepatocelulares com pigmento “Dubin-Johnson like” (derivado da lipofuscina e pigmentos biliares)
- Associados ao aumento do risco de atípia e malignidade

Descrito previamente em HCC!

[1] Taofic Mounajjed, Saba Yasir, Patrice A Aleff and Michael S Torbenson. Pigmented hepatocellular adenomas have a high risk of atypia and malignancy. Modern Pathology (2015) 28, 1265–1274; doi:10.1038/modpathol.2015.83; published online 24 July 2015

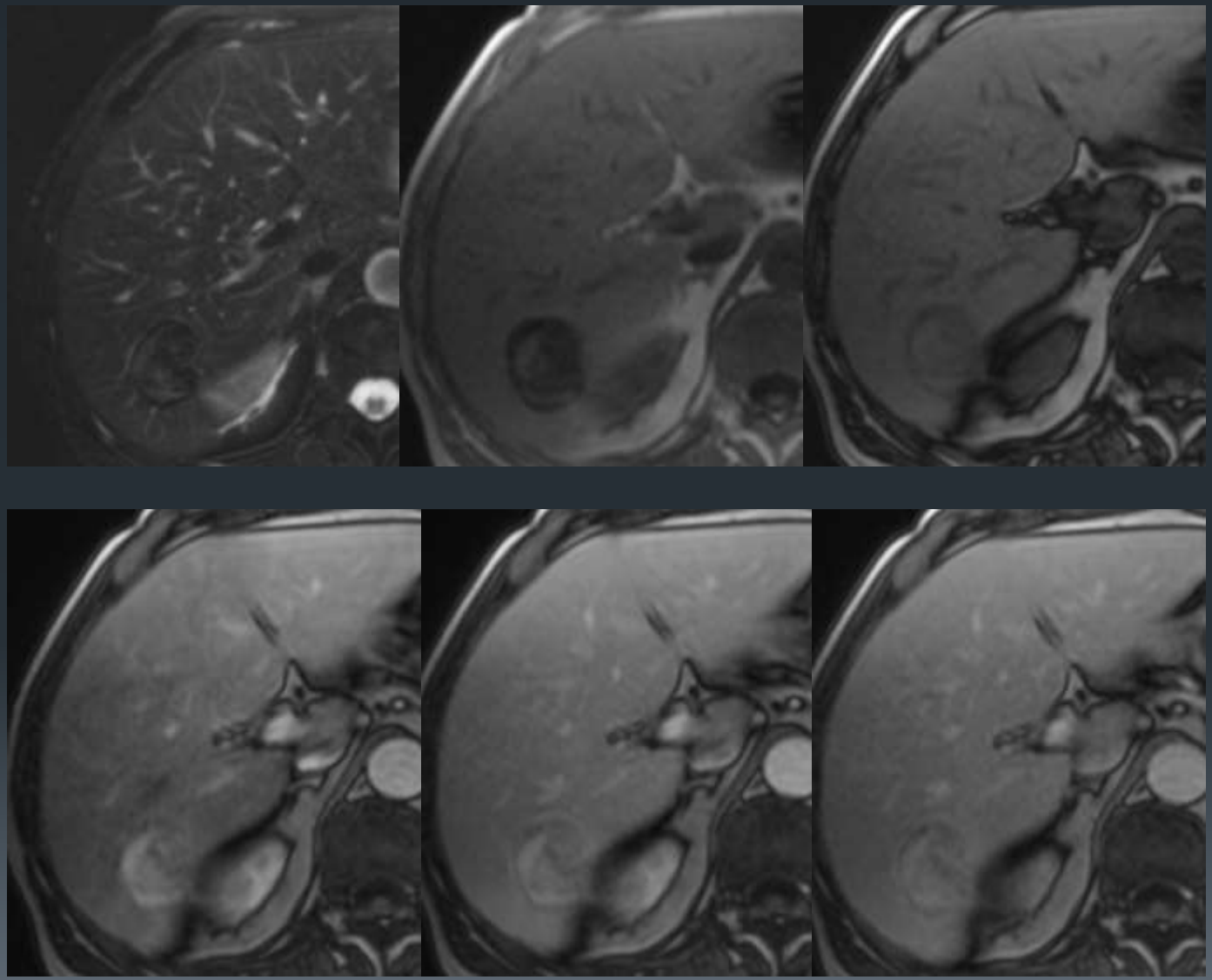

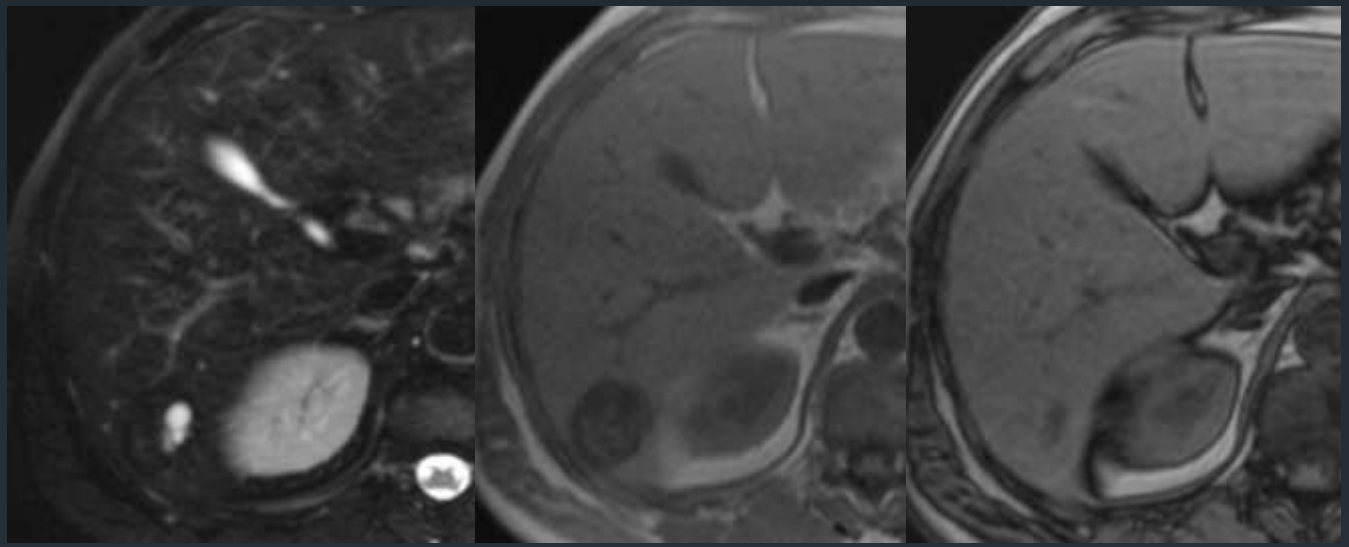

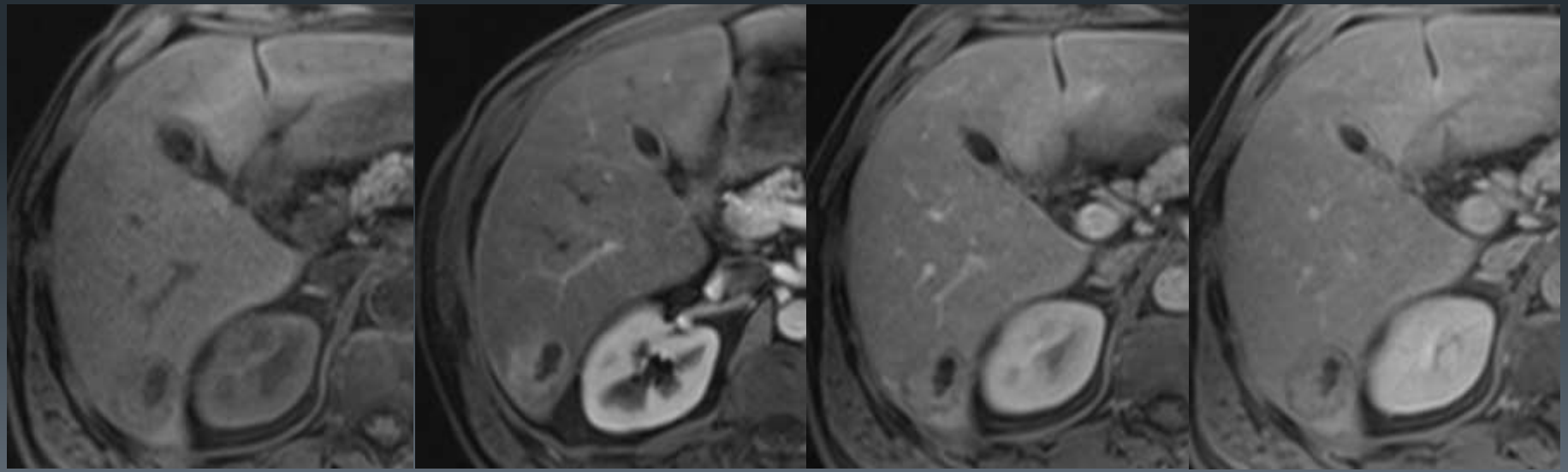

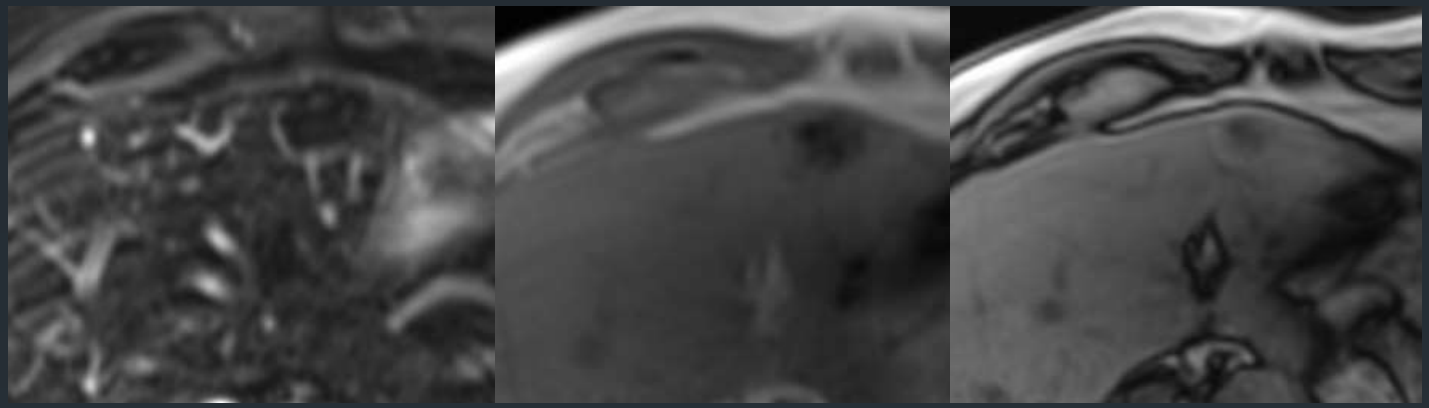

- Adenoma hepatocelular **inflamatório** com **mutação da β-catenina**, siderótico e com pigmento de lipofuscina.

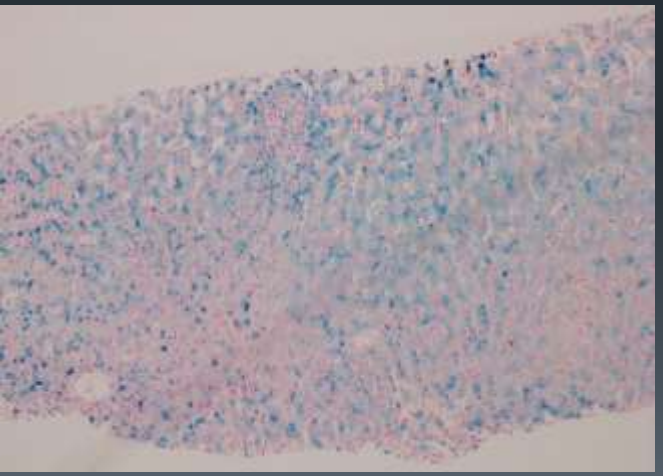

Annals of Hepatology

The Official Journal of the Mexican Association of Hepatology, the Latin-American Association for Study of the Liver and the Canadian Association for the Study of the Liver

CASE REPORT

July-August, Vol. 15 No. 4, 2016: 598-603

Pigmented hepatocellular adenoma with β-catenin activation: case report and literature review

Rosa Coelho,* Regina Gonçalves,* Fátima Carneiro,**,*** Margarida Fernandes,** Joanne Lopes,** Susana Guimarães,** Guilherme Macedo*

* Gastroenterology Department, Centro Hospitalar São João, Porto. Portugal.
** Pathology Department, Centro Hospitalar São João, Porto. Portugal.
*** IPATIMUP, Institute of Molecular Pathology and Immunology of the University of Porto, Porto. Portugal.

ABSTRACT

Hepatocellular adenomas (HCAs) are benign liver tumors recently characterized into 4 different types according to genetic, pathological and clinical features. The prognosis is not well established yet and malignant transformation has been recently associated with β-catenin activation. We aimed to describe a case of a pigmented HCA with β-catenin nuclear expression and inflammatory features and to review the cases of pigmented HCAs in the literature. We report a case of a young female patient without contraceptive use, with a liver tumor diagnosis. Liver biopsy revealed diffuse expression of β-catenin and a partial hepatic resection was performed. The histologic analysis revealed a hepatocellular tumor composed of uniform trabeculae of hepatocytes and solid areas, the later with a significant amount of black pigment highlighted by Masson-Fontana stain. Immunohistochemistry showed co-expression of C-reactive protein and serum amyloid A in the tumor. Literature review revealed that pigmented HCAs, previously reported as dark adenomas, are rare tumors. In HCAs, the presence of β-catenin activation should be searched for due to the higher risk of malignant transformation in hepatocarcinoma. We describe a pigmented HCA with β-catenin nuclear expression and inflammatory features being the fifth case reported so far.

Key words. Liver cell adenoma. Pigment. Dubin-Johnson pigment. Glutamine synthetase. Liver cell.

Obrigada